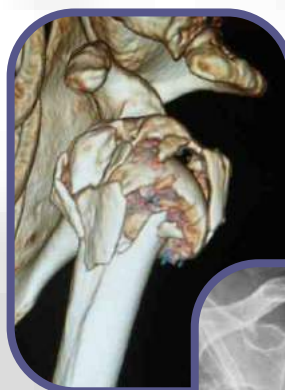
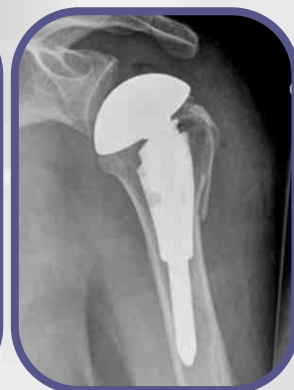
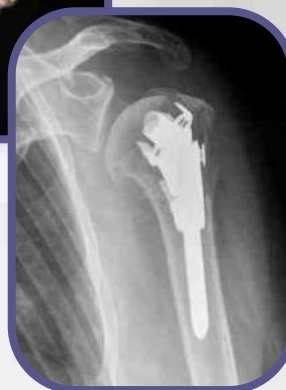Evolutis

CREATEUR FABRICANT



**JUST
UNIC®**



Evolutis
MOTION INSIDE

*Surgical
Technique*

Jack-Up Shoulder prosthesis for Trauma indications

Adjustable shoulder prosthesis for complex fractures.

The Just Unic humeral implant is indicated for the repair of 3 or 4 part proximal humerus fractures irrespective of bone quality

((1) Report on 26 Bilboquet devices with an average follow up of 25 months. "The peripheral support of the humeral head is optimal in resisting varus displacement").

This system allows for rapid and controlled, stable anatomical osteosynthesis of complex fractures of the upper extremity of the humerus

((2) Prospective study of 22 Bilboquet cases with average follow up of 34 months: "Consolidation was obtained in all cases. There was no secondary tilt of the head, nor migration or non-union of the tuberosities").

The impaction of the staple into the cancellous bone of the head provides a firm support which allows for efficient distraction. The stem/sleeve placed in the humeral diaphysis shaft allows for adjustable height distraction of the fracture site to restore anatomic "Gothic arch" metaphyseal – cephalic position. Subsequent tuberosity re-attachment with sutures is facilitated.

The system was developed by Pr. Levon Doursounian (University Hospital St. Antoine, Paris) in the 1990s allowing for regular tuberosity and humeral head consolidation. In cases of symptomatic avascular necrosis of the humeral head, it is possible to transform the system from an osteosynthesis device to a hemi prosthesis by removing the staple and exchanging it for a head, placed on the same morse taper of the stem.

If the indication justifies a prosthesis (in particular fracture – dislocations) then the system allows for simple prosthetic head height adjustment and optimum tuberosity repair.

(1) A new internal fixation technique for fractures of the proximal humerus - the Bilboquet device: a report on 26 cases. L. Doursounian et Al. Dept of Orthopaedic Surgery, HEGP, Paris, France. J Shoulder Elbow Surg. July/August 2000: 279-288

(2) Complex proximal humeral fractures: A prospective study of 22 cases treated using the "Bilboquet" device L. Doursounian", A. Kilinc, B. Cherier, G. Nourissat Department of Orthopaedic Surgery and Traumatology, Saint-Antoine University Hospital, Paris, France, Orthopaedics & Traumatology: Surgery & Research (2011) 97, 58—66



Prosthetic humeral head: indicated in cases of humeral head de-vascularisation

Table of contents

•	Presentation of the JUST UNIC concept	page 2
•	Table of contents	3
•	Indications	4
•	Place in the therapeutic arsenal	4
•	Installation	4
•	Surgical approach	5
•	Surgical technique	5
o	Fracture site exploration	5
o	Lifting the humeral head	5
o	Choice of the head staple	6
o	Implanting the staple	6
o	Diaphysis preparation	7
o	Stem/sleeve trials	7
o	Introduction of the stem/sleeve	8
o	Assembly of the stem and the head staple	8
o	Reduction	8
o	Tuberosity re-insertion	9
•	Closure and post-operative care	9
•	Clinical cases	10
•	Snapshots of the instrument tray	11
•	Implant and Instruments list	12

Disclaimer :

This document is intended to be read only by experienced orthopaedic surgeons familiar with the surgical implantation of shoulder arthroplasty, and by individuals related to or acknowledged by the Evolutis company.

This publication is intended as the recommended procedure for using the Evolutis JUST UNIC shoulder implants. It offers guidance only. Evolutis is the manufacturer of the device. As such and claiming no medical skill, Evolutis does not recommend a specific use of a product or a technique.

Each surgeon should consider the particular needs of the patient and make appropriate adjustments where necessary.

For any additional information related to the products, the indications and contra indications, the warnings and precautions of use, and the adverse effects, please refer to the INSTRUCTION FOR USE leaflet included in the packaging of the implants. For further advice please contact your local representative.

Brand and products are protected for copyrights. It is strictly forbidden unless authorized by the Evolutis company, to duplicate or copy whole or part of this document.

Indications

3 part humeral epiphysis fracture in osteoporotic bone associated with metaphysis comminution.

4 part fractures (except where the head is no longer attached at all)

Fracture dislocation in patients under 55 years of age (with conservation of autologous osteo – cartilaginous bone graft).

Place in the therapeutic arsenal

On average for every 100 proximal humerus fractures:

20% are treated by prosthetic arthroplasty

53% are osteosynthesised by either centromedullary nail or locking screw-plates

27% can potentially be treated by a system with stem and humeral head staple.

Installation

The patient should be installed in a semi sitting position with the head held in a head brace (or adhesive tape) (Fig 1) avoiding hyper-extension.

The affected arm should be free (Fig 2). The Fluoroscopy C arm should be positioned in order to give a clear view of the superior extremity of the humerus and the gleno-humeral articulation.

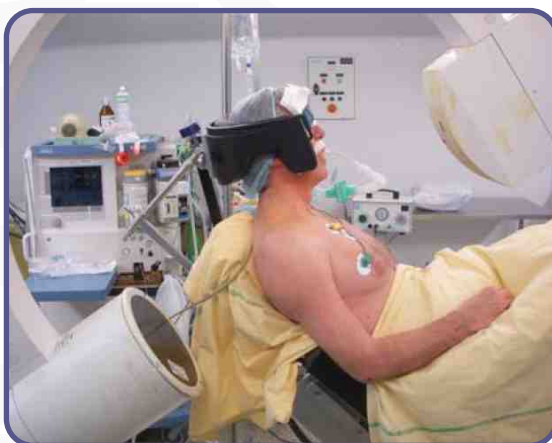

Figure 1

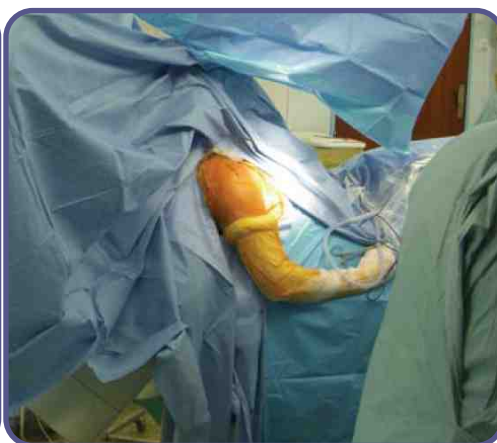

Figure 2

Surgical approach

The approach can be either delto pectoral or supero-lateral. The delto pectoral approach is essential in cases of metaphyseal – diaphyseal comminution or large displacement of the lesser tuberosity. The supero – lateral approach allows for a good exposure of the greater tuberosity usually displaced posteriorly.

Supero Lateral approach

The muscle – fascia opening starts at the superior part and passes anterior to the acromion leaving the fibrous tissue anterior to the muscular opening. (Fig 3a) This precaution facilitates closing the deltoid at the end of the operation. Section the coraco-acromial ligament to facilitate the exposure. Dissect the deltoid distally taking care not to damage the axillary nerve. After dissection of the deltoid the deltoid bursa can be opened to evacuate the haematoma (Fig 3b). The bursa is then cut away to facilitate fracture site exposure.

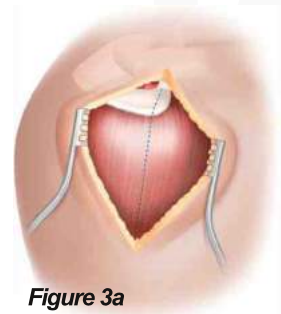


Figure 3a

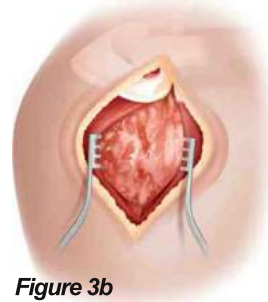


Figure 3b

Fracture site exploration

Initially the fracture site should be explored by finger in order to understand the nature of the fracture and avoid aggravating it. This should be done carefully and progressively in order to avoid puncturing the gloves on sharp bone fragments. In the more simple cases the fracture site is well exposed after washing and the cartilage of the head presents quite horizontally (Fig 4a and b). In other cases the tuberosities are still attached by soft tissue and so obscure the view. In these cases it is necessary to explore the inter-tuberosity fracture with the finger. Slightly enlarge the fracture line with a ruginator or small retractor. In the majority of cases it is recommended to conduct a tenodesis of the long biceps tendon.

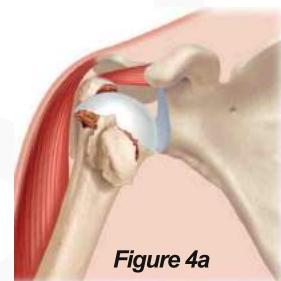


Figure 4a

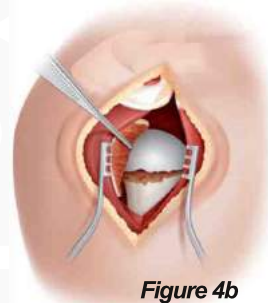


Figure 4b

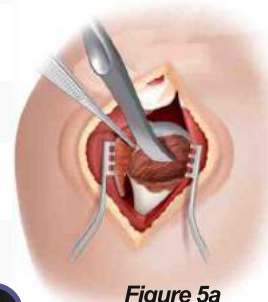

Figure 5a

Lifting the humeral head

After exposing the fracture site lift the humeral head with the aid of a ruginator (Fig 5a) or finger (Fig 5b) and carefully position in front of the glenoid.

When using the finger the manoeuvre should be as follows:

Place the thumb against the cancellous bone of the head, and push in the direction of the glenoid whilst simultaneously pulling down on the wrist of the patient in order to apply traction on the humerus and open up the fracture site (Fig 6a).

Check the partial humeral head reduction with the C arm (Fig 6b) and confirm with a direct view of the cancellous bone of the humeral head in the wound site. Check that the head has remained well attached to the soft tissues by applying slight traction using forceps.

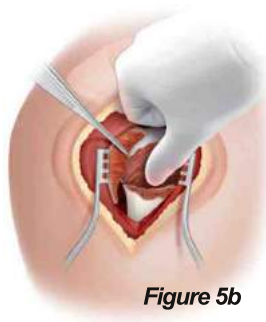


Figure 5b

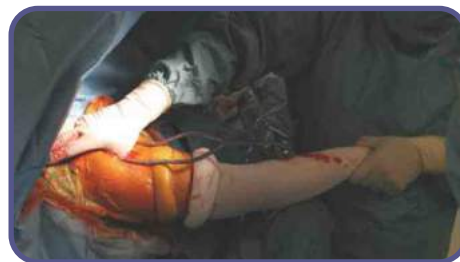

Figure 6a

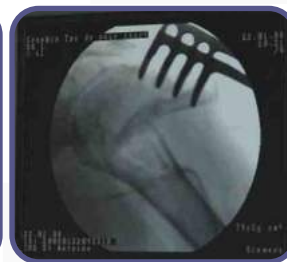

Figure 6b

Choice of the head staple

Select one of the 4 trial staples.

Choose the size which covers the most in order to ensure good peripheral loading and also avoiding positioning errors (excessively anterior or in the lesser tuberosity)

Place the trial on the staple holder.

Place the point of the trial centrally against the cancellous bone of the head (Fig 7a).

In more elderly patients the position is often easier to identify due to less bone stock available. But in younger patients it may be necessary to flatten off the surface of the cancellous bone of the head before positioning the trial.

Check the position and size of the trial with the c arm (7b).

Often the trial goes into a superior eccentric position, re-position if possible, but without compromising the vascularisation of the head. A staple which is in a slightly superior eccentric position will not adversely affect the results.

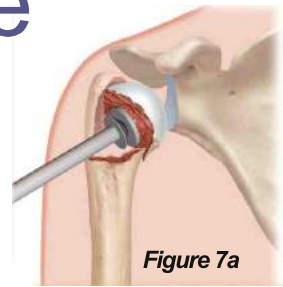


Figure 7a

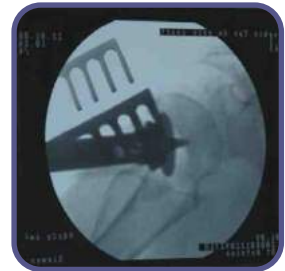

Figure 7b

Implanting the staple

Select the staple of the same size as the best fit trial on the staple holder.

Check that the head is still properly positioned in front of the glenoid.

Centre the staple over the imprint left by the trial in the cancellous bone and impact it using a hammer up until the flat surface is in contact with the cancellous surface (Fig 8a).

If the cancellous bone is dense it may be necessary to curette the bone before impacting the central cone.

In all cases curette the bone inside the central cone (Fig 8b) after implantation of the staple.

Check with the C arm that the staple is in a good position: anteversion or retroversion errors of positioning will correct themselves once the head is placed over the diaphysis component (Fig 9).

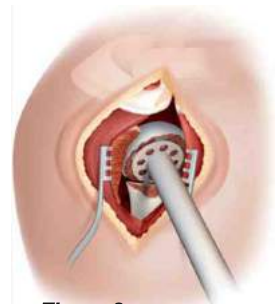


Figure 8a

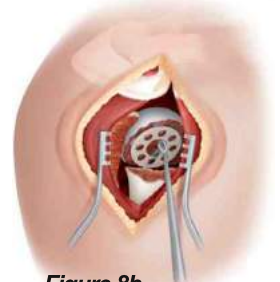


Figure 8b

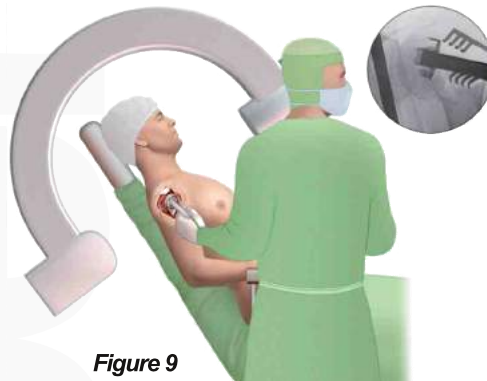


Figure 9

Preparation of the diaphysis

Diaphysis preparation starts with the positioning of the tuberosity sutures and tension banding.

Expose the proximal humerus by pushing up the humerus at the elbow.

Ruginate the lateral cortex to avoid the axillary nerve.

Place a Hohmann retractor and drill the lateral cortex with two holes using a 3,5mm drill (Fig 10a) taking the precaution not to further split the fracture or fracture around the drill holes, do not try and use a bone awl first.

Position the arm in internal rotation for the posterior hole and then external rotation for the anterior hole and slightly outside the bicipital groove.

Thread two Ethibond N°6 sutures through the two holes (Fig 10b) and temporarily tie off with forceps.

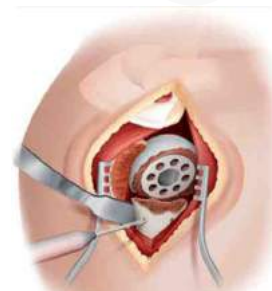


Figure 10a

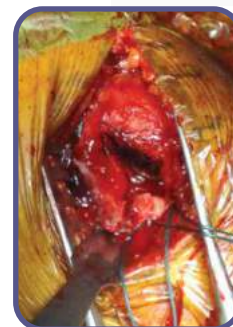


Figure 10b

Stem/sleeve trials

Three sizes of stem/sleeve are available. Trials enable to select the best size of implant and position in terms of height and retroversion.

Proximal humeral bone loss is often about 5 to 15mm and difficult to evaluate accurately.

Explore the humeral diaphysis with a curette in order to assess the medullary geometry.

Start with the smallest trial (8S) (Fig 11a).

Follow the patient's retroversion, about 20° on average, and check that the trial is well blocked in the humeral shaft. The correct size is when the supero medial edge is at the level of or just under (3 to 5mm) the medial cortical edge of the fracture (Fig 11b).

Do not hammer the trial.

Go up in sizes incrementally to find the best fit and height.

A properly positioned trial will avoid a too high position whereby the stem cannot fit into the sleeve or a position which is too low which will inhibit good fracture reduction.

Check the good position of the trial using the C arm (Fig 11c).

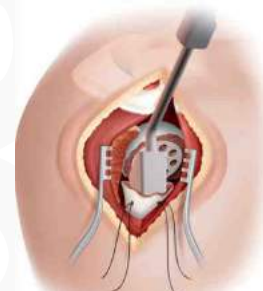


Figure 11a

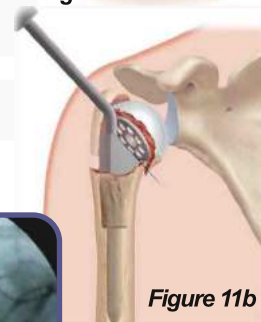

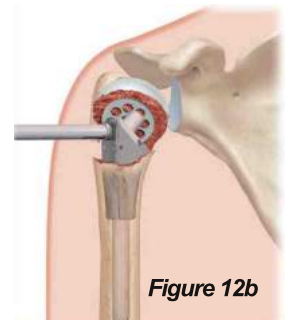
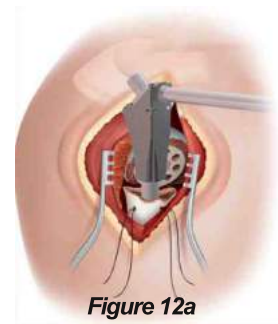
Figure 11b

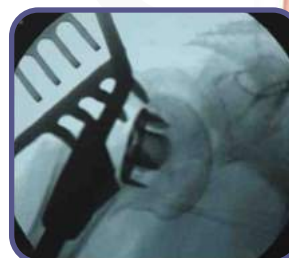

Figure 11c

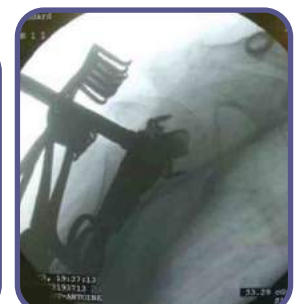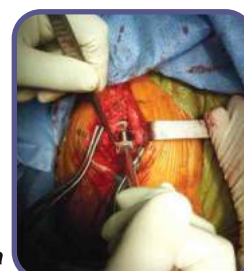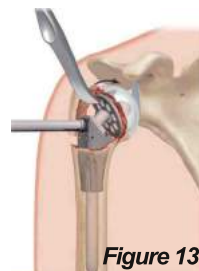Implanting the stem/sleeve

The stem, sleeve and locking screw are all packaged together. Select the size determined by the trials. Open the packaging and keep the locking screw to one side. Introduce the stem into the sleeve and lock them together using the stem holder (Fig 12a). Slide the components into the humerus (Fig 12b) by holding the arm and making small movements but without impacting.



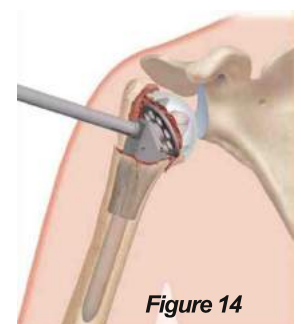
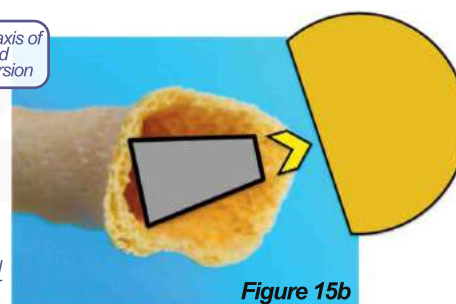
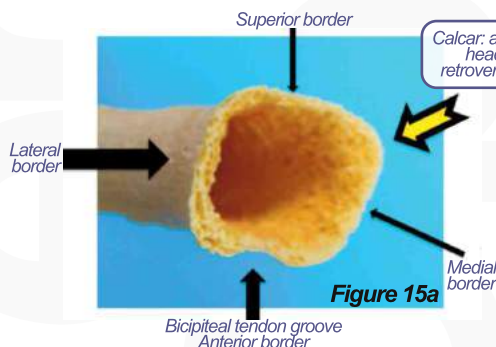
Connecting the stem to the staple

With the arm in rotation and abduction place the morse taper of the stem inside the female taper part of the staple. If necessary assist the orientation of the head of the humerus by guiding it with a ruginator so that both morse taper parts are aligned (Fig 13 a and b). Check with the C arm that orientation is correct before proceeding (Fig 13c).



Reduction

- There are two important parameters concerning the reduction:
- The first is the height which can be initially assessed by lifting the head and stem using the holder (Fig 14).
 - The second is the correct position of the stem/sleeve in the axial plane, which is the retroversion. This should be conducted as it was for the trial. The proximal part of the metaphysis can be seen as having a trapezium shape, the calcar being at the point where the medial and posterior borders of the metaphysis meet (Fig 15a and b) which help indicate the best orientation. When the calcar is fractured, the correct orientation corresponds to the defect.



Reduction (continued)

When the global proximal morphology of the proximal humerus has been checked by C arm, the anatomical arch must be re-established.
Place the longer prong of the jack into the proximal hole anterior hole of the stem and the shorter prong resting on the anterior part of the groove in the sleeve (Fig 16a) and progressively tighten to distract click by click (5mm increments), until the best restitution of the anatomical arch is achieved (Fig 16b).
Check by C arm.
Correct distraction is also when there is some tension on the fracture and the soft tissues but without creating a space between the medial cortex and the head.
The 4 positions allow for up to 2cm of correction.
Lock the assembly using the locking screw at the require height (Fig 17).
Remove the jack.
Continue the diaphysis – head osteosynthesis and check the efficiency of the fixation by moving the shoulder in all direction.

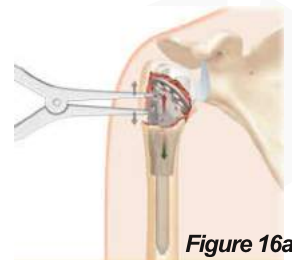


Figure 16a

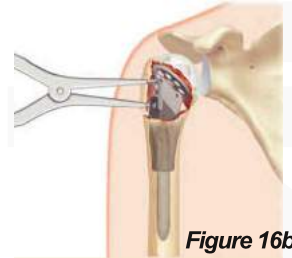


Figure 16b

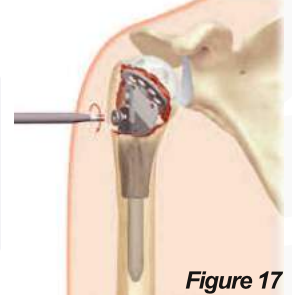


Figure 17

How to evaluate the distraction?



Method 1

The overall muscle-bone assembly is stable.
Arm movements are transmitted in a normal fashion to the head.
Head height relative to the medial diaphysis is correct.
The jack offers some resistance to going up a notch.

Method 2

The lateral bone defect corresponds to the size of the greater tuberosity needing to be re-positioned.
If the fragment is larger than the defect, jack up the head by one click.
If the fragment is smaller than the defect, bring the head down a notch.



Tuberosity re-insertion

This step is very important as it affects the successful functional outcomes of the shoulder.
The greater tuberosity fixation sutures can be attached directly onto the implant locking screw, the head of which is a pulley type shape and allows for two 1mm threads to be used. This allows to avoid a trans osseous fixation and to tie the threads coming from the cuff directly into the locking screw.
For 3 part fractures a double tension banding can be reinforced with one or two horizontal sutures running from the lesser tuberosity to the posterior part of the greater tuberosity (Fig 18).

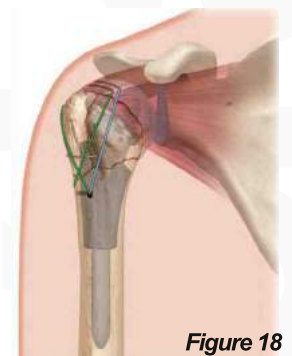
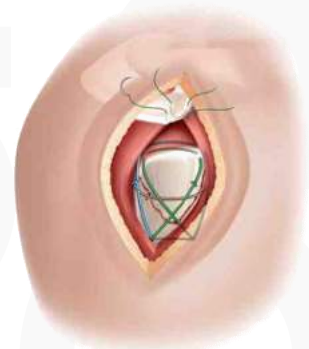


Figure 18

Closure and postoperative care

Carefully re-attach the deltoid to its superior portion with 2 or 3 trans osseous sutures using Vicryl 2.
Close both planes using a drain.
Immobilise with elbow to body using a Dujarier type brace. Possible use of an abduction cushion and rotational control.
Remove drain and re-dress the wound at 48h.
Re-education can commence at the 4th or 5th day post operatively when postoperative pain has subsided.
Passive re-education for 3 weeks (for example auto re-education with pendulum movements of the arm whilst bent forward).
Active re-education after 3 weeks to 3 months.



Clinical case #1

4 part fracture in a 75 year old male.

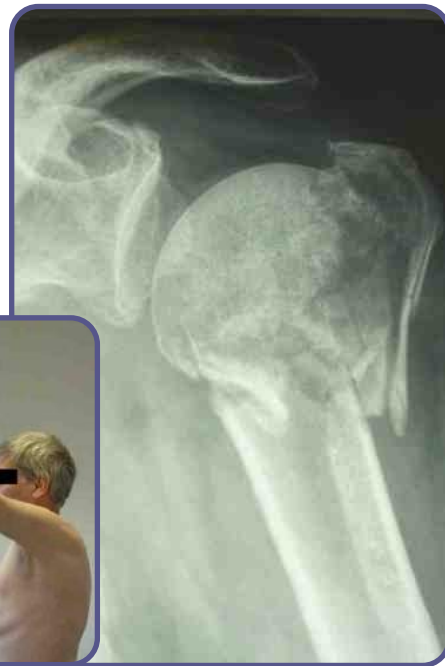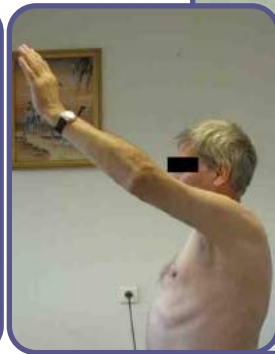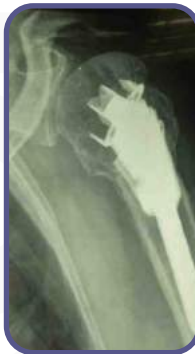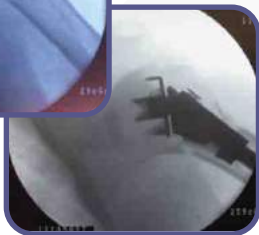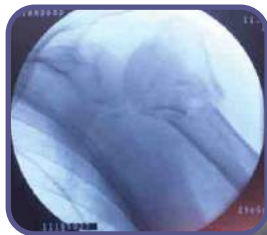Pre-operative C arm.

Aspect at the end of the operation: re-establishment of the anatomical arch; the staple is slightly superior.

Locking was achieved with a jack up of one position.

X ray at 24 months.

Active forward elevation at 24 months, brut Constant score 77, modified 100.



Clinical case #2

3 part fracture in a 76 year old female.

Pre-operative C arm.

Aspect under C arm at the moment of locking screw tightening at the 2nd jack up position.

Re-establishment of the anatomical arch, with the staple in slightly superior position.

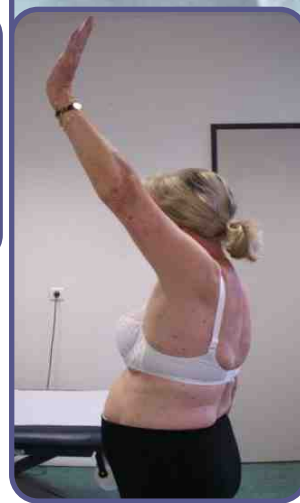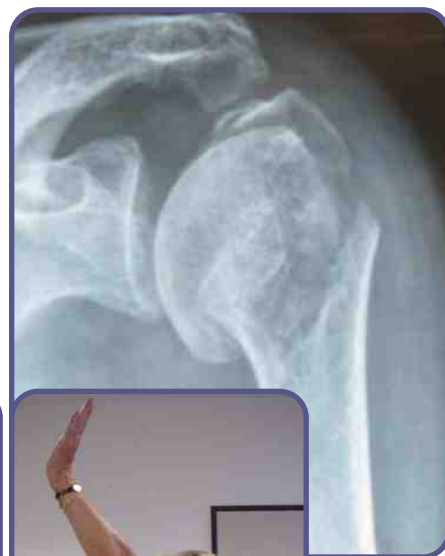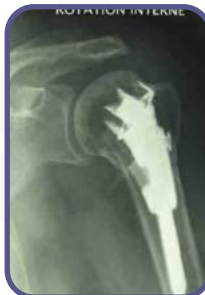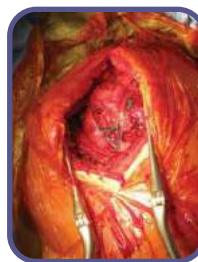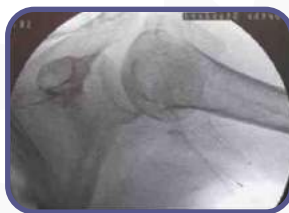Greater tuberosity not re-attached at this stage before closure.

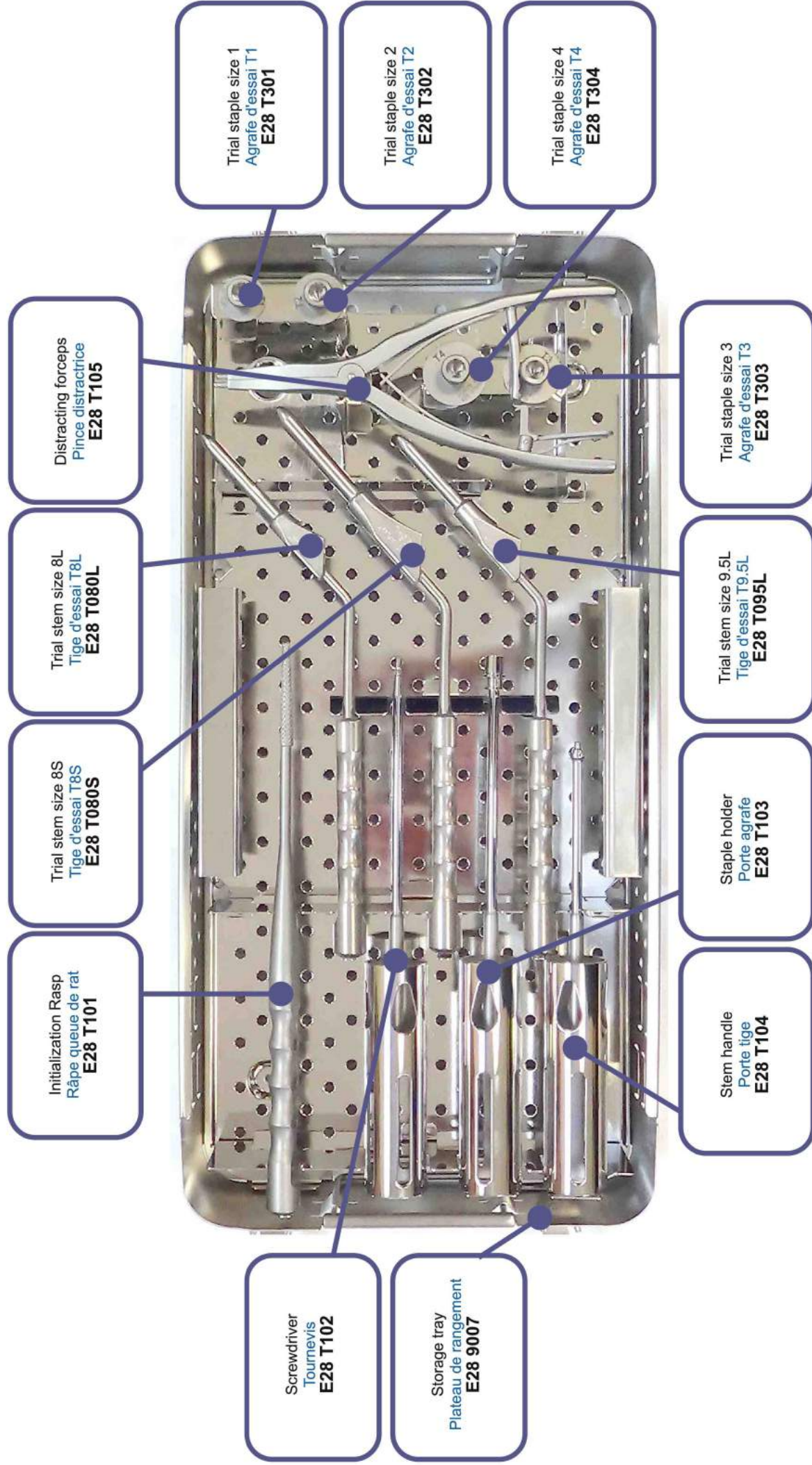
Aspect of greater tuberosity reinsertion with double 8 tension banding.

Intraoperative aspect after reinsertion of the greater tuberosity.

X ray at 14 months.

Active forward elevation at 14 months, brut Constant score 82, modified 100.






References

Implants JUST UNIC® Implants

Description	Size Taille	Cat N° Réf.
Humeral sleeve, stem and screw set / <i>Ensemble cale, tige et vis</i>	8S	E27 T080S
Humeral sleeve, stem and screw set / <i>Ensemble cale, tige et vis</i>	8L	E27 T080L
Humeral sleeve, stem and screw set / <i>Ensemble cale, tige et vis</i>	9.5L	E27 T095L
Humeral head staple / <i>Agrafe pour tête humérale</i>	S1	E27 T301
Humeral head staple / <i>Agrafe pour tête humérale</i>	S2	E27 T302
Humeral head staple / <i>Agrafe pour tête humérale</i>	S3	E27 T303
Humeral head staple / <i>Agrafe pour tête humérale</i>	S4	E27 T304
Hollow humeral head / <i>Tête humérale creuse</i> Centered / <i>Centrée</i>	Ø40	E27 T140
Hollow humeral head / <i>Tête humérale creuse</i> Centered / <i>Centrée</i>	Ø43	E27 T143
Hollow humeral head / <i>Tête humérale creuse</i> Centered / <i>Centrée</i>	Ø47	E27 T147
Hollow humeral head / <i>Tête humérale creuse</i> Centered / <i>Centrée</i>	Ø50	E27 T150
Hollow humeral head / <i>Tête humérale creuse</i> Offset / <i>Excentrée</i>	Ø40	E27 T240
Hollow humeral head / <i>Tête humérale creuse</i> Offset / <i>Excentrée</i>	Ø43	E27 T243
Hollow humeral head / <i>Tête humérale creuse</i> Offset / <i>Excentrée</i>	Ø47	E27 T247
Hollow humeral head / <i>Tête humérale creuse</i> Offset / <i>Excentrée</i>	Ø50	E27 T250
Locking screw / <i>Vis de blocage</i>		E27 T001
Instrumentation set / <i>Instrumentation ancillaire</i>		E28 9107



JUST UNIC Instrumentation
set E28 9107

JUST UNIC®

Materials:
Stem, Dock, Staple and Screw: Titanium alloy (TA6V) according ISO 5832-3
Humeral head: Cobalt-Chromium according ISO 5832-4
Sterilized under Gamma irradiation



Designed and
Manufactured in
France